



PRESENTING CLINICAL SIGNS

History: Presented on 2/23/22 for acute onset of central vestibular signs. Radiographs revealed mild cardiomegaly with tortuous great vessels. No murmur. HW positive, microfilaria negative.

DATE

3/1/22

ECHOCARDIOGRAPHIC FINDINGS

2D, M-mode, and Doppler study.

PERFORMED BY

Tom McNeill

Left atrial size is normal. The mitral valve is normal. Left ventricular dimensions are normal. Left ventricular systolic function is normal. The aorta and aortic valve are normal. Right atrial and right ventricular dimensions are normal. The tricuspid valve is normal. The pulmonary artery and pulmonic valve are normal. No heartworms are visualized. No shunting lesions are visualized. No pericardial effusion or cardiac masses are seen.

INTERPRETED BY

Keith Blass, DVM,
MS, DACVIM
(Cardiology)

LA - 38.0 mm
LVIDd - 39.7 mm
LVIDs - 24.6 mm
FS - 38%
RA - 31.3 mm
LVOT - 1.15 m/s
RVOT - 1.45 m/s

PATIENT

Keane Mortensen

ASSESSMENT/RECOMMENDATIONS

Normal echocardiogram

SPECIES

Canine

This examination demonstrates no evidence of structural heart disease, nor does it demonstrate any worms in Keane's right heart chambers or main pulmonary artery, suggesting that her worm burden is relatively low.

BREED

German Shepherd

No reason for Keane's vestibular episode is appreciated in the image set.

A four week course of doxycycline (10 mg/kg BID) is recommended in order to treat the heartworm symbiont Wolbachia, as is initiation of a monthly heartworm preventive.

SEX

FS

No contraindication to beginning heartworm adulticide therapy one month following the completion of doxycycline is appreciated in the image set. Strict exercise restriction is recommended throughout the course of therapy.

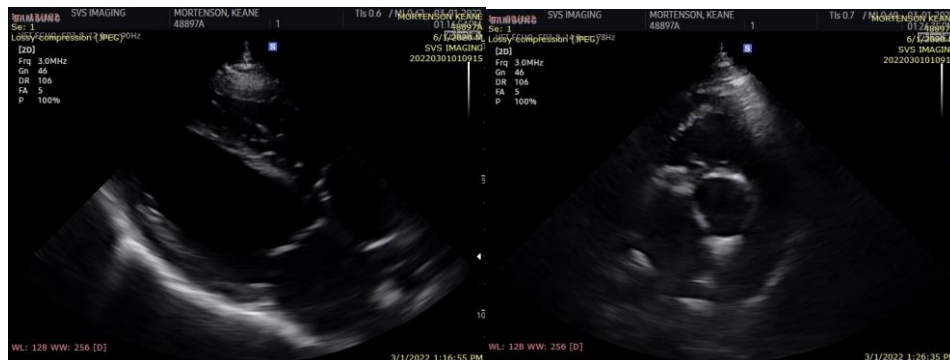AGE

1 y

A recheck echocardiogram is recommended if new physical exam and/or clinical abnormalities suggestive of cardiac dysfunction develop. A heartworm antigen test is recommended 9 months after the final melarsomine injection.

WEIGHT

38.5 kg

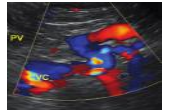


HOSPITAL NAME

SVS Imaging CT

REFERRING VET

Dr. Delamaide



DATE

3/1/22

The information and recommendations provided are based on the images presented by the referring veterinarian. No evaluation can be communicated regarding pathology that was not visible in the image/video clips provided.

Thank you for this referral. If the clinical or image interpretation does not parallel your findings or if I can be of any further assistance please contact me.

PERFORMED BY

Tom McNeill

Keith Blass, DVM, MS, DACVIM (Cardiology)

KeithBlass@gmail.com

631-804-5754

INTERPRETED BY

Keith Blass, DVM,
MS, DACVIM
(Cardiology)

PATIENT

Keane Mortensen

SPECIES

Canine

BREED

German Shepherd

SEX

FS

AGE

1 y

WEIGHT

38.5 kg

HOSPITAL NAME

SVS Imaging CT

REFERRING VET

Dr. Delamaide